

# Limb salvage surgery complimented by customised mega prostheses for malignant fibrous histiocytomas of bone

**MV Natarajan**

Department of Orthopaedics and Trauma, Madras Medical College and Research Institute, Government General Hospital, Chennai, India

**P Mohanlal**

Medway Maritime Hospital, Gillingham, Kent, United Kingdom

**JC Bose**

Department of Surgical Oncology, Government Royapettah Hospital, Chennai, India

---

## ABSTRACT

**Purpose.** To assess functional and oncological outcomes of patients with malignant fibrous histiocytomas of bone, after limb salvage surgery complimented by a customised prosthesis.

**Methods.** Between May 1991 and December 2002, 15 men and 5 women (mean age, 42 years) with histologically proven malignant fibrous histiocytoma of bone underwent treatment involving limb salvage surgery complimented by a customised mega prosthesis. Most of the tumours were stage II according to the Enneking system, and located around the knee. Wide resection margins were achieved in 18 patients.

**Results.** Following a mean follow-up of 58 months, 4 patients underwent amputation for local recurrence and 5 died of the disease. Two patients had prosthesis fractures; revision of the prosthesis was carried out in one. The functional result was excellent in 5 and good in 9 patients. The Kaplan-Meier 5-year survival rates of the patients treated without chemotherapy and with chemotherapy were 50% and 76%, respectively.

**Conclusion.** Limb salvage surgery with chemotherapy is a viable treatment option for patients with malignant fibrous histiocytoma of bone. It achieves higher survival rates than resection alone. Such therapy improves quality of life and provides a useful and functional limb.

**Key words:** bone neoplasms; histiocytoma, malignant fibrous; limb salvage; prosthesis implantation; survival rate

---

## INTRODUCTION

Malignant fibrous histiocytoma (MFH) of the bone is a rare tumour of unknown origin, accounting for <2% of all primary malignant bone tumours.<sup>1</sup> Being aggressive, it is characterised by a high frequency of local recurrence and metastasis to regional lymph nodes and distant sites. A combined approach involving wide surgical resection and neo-adjuvant chemotherapy is recommended.<sup>2-4</sup> Surgical reconstruction techniques include the use of customised prostheses, resection-arthrodesis, allograft, or rotationplasty depending on the tumour's location and extent of resection.

**Table**  
Demographic and clinical characteristics and outcomes of the 20 patients

Patient No.	Sex/age (years)	Involved site	Tumour stage	Prosthesis type*	Resection margin	Chemotherapy	Follow-up (months)	Complications	Functional result	Oncological result†
1	F/25	Distal femur	IIB	TKP	Wide	No	36	Prosthetic fracture	Fair	DOD
2	M/48	Proximal tibia	IIA	TKP	Wide	No	152	Prosthetic fracture, local recurrence	Fair	NED
3	M/50	Distal femur	IIA	TKP	Wide	No	8	Skin infection, local recurrence	Poor	DOD
4	M/50	Proximal humerus	IIA	PHP	Wide	No	110	-	Excellent	CDF
5	M/60	Proximal humerus	IA	PHP	Marginal	No	12	-	Fair	DOD
6	M/41	Distal femur	IB	TKP	Wide	No	98	-	Good	CDF
7	M/38	Proximal tibia	IB	TKP	Wide	Yes	84	-	Excellent	CDF
8	M/52	Distal femur	IIA	TKP	Wide	Yes	44	-	Good	DOD
9	F/50	Distal femur	IB	TKP	Wide	Yes	80	-	Good	CDF
10	M/52	Proximal tibia	IIA	TKP	Wide	Yes	75	-	Excellent	CDF
11	M/51	Distal femur	IIB	TKP	Contaminated	Yes	72	Local recurrence	Poor	NED
12	M/54	Distal femur	IIB	TKP	Wide	Yes	54	-	Good	DOD
13	F/16	Proximal tibia	IIA	TKP	Wide	Yes	65	Skin necrosis	Good	CDF
14	M/35	Distal femur	IIB	TKP	Wide	Yes	47	Local recurrence	Fair	NED
15	F/37	Proximal femur	IIB	PFP	Wide	Yes	45	-	Excellent	CDF
16	F/30	Proximal femur	IIB	PFP	Wide	Yes	45	-	Good	CDF
17	M/42	Distal femur	IIB	TKP	Wide	Yes	44	-	Good	CDF
18	M/14	Proximal tibia	IIA	TKP	Wide	Yes	36	-	Excellent	CDF
19	M/45	Proximal femur	IIB	PFP	Wide	Yes	24	-	Good	CDF
20	M/49	Proximal humerus	IIB	PHP	Wide	Yes	24	-	Good	CDF

\* TKP denotes total knee prosthesis, PHP proximal humeral prosthesis, and PFP proximal femoral prosthesis

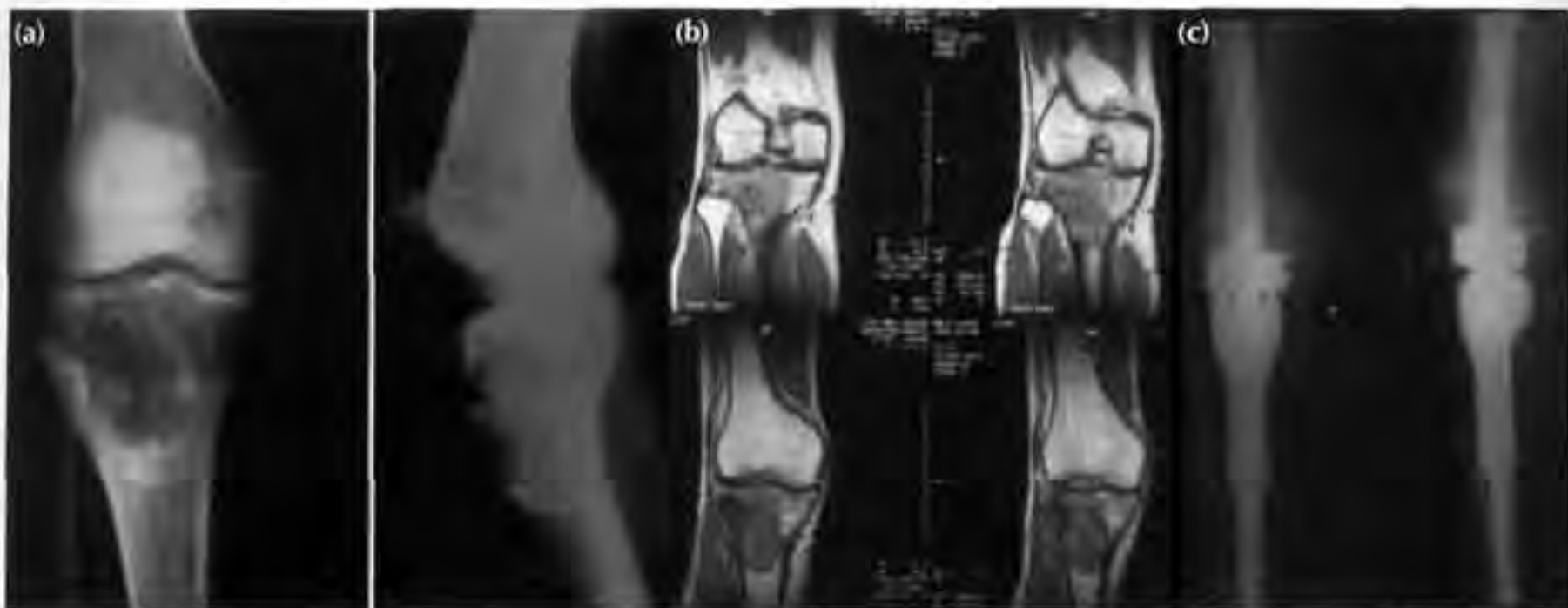† DOD denotes died of disease, NED no evidence of disease, and CDF continuously disease free

Customised prostheses give good limb function.

## MATERIALS AND METHODS

Between May 1991 and December 2002, 15 men and 5 women aged 14 to 60 (mean, 42) years with histologically diagnosed MFH of bone underwent limb salvage and reconstruction with a customised mega prosthesis. The knee was most commonly involved (distal femur [n=9], proximal tibia [n=5]), followed by proximal femur (n=3) and proximal humerus (n=3) [Table]. 14 patients treated after 1996 received chemotherapy. Assessments were made using radiography, computed tomography (CT), magnetic

resonance imaging (MRI), technetium bone scanning, and tumour angiography. Tumour staging was carried out according to the Enneking system.<sup>5,6</sup> All defects were reconstructed with custom-made prostheses. There were no intra-operative complications. Functional outcome was assessed using Enneking's modified system of functional evaluation of surgical management for musculoskeletal tumours.<sup>7</sup> The latter included measuring criteria for: motion, pain, stability, deformity, strength, functional activity and emotional acceptance. To check for recurrence, metastasis, or implant-related complications, all patients were followed up monthly for the first 6 months, 3-monthly for the next 3 years, and annually thereafter. The mean follow-up period was 58 (range,



**Figure 1** Preoperative (a) radiographs and (b) coronal T1-weighted magnetic resonance images showing malignant fibrous histiocytoma of the proximal tibia. (c) Follow-up radiographs after reconstruction with total knee prosthesis.

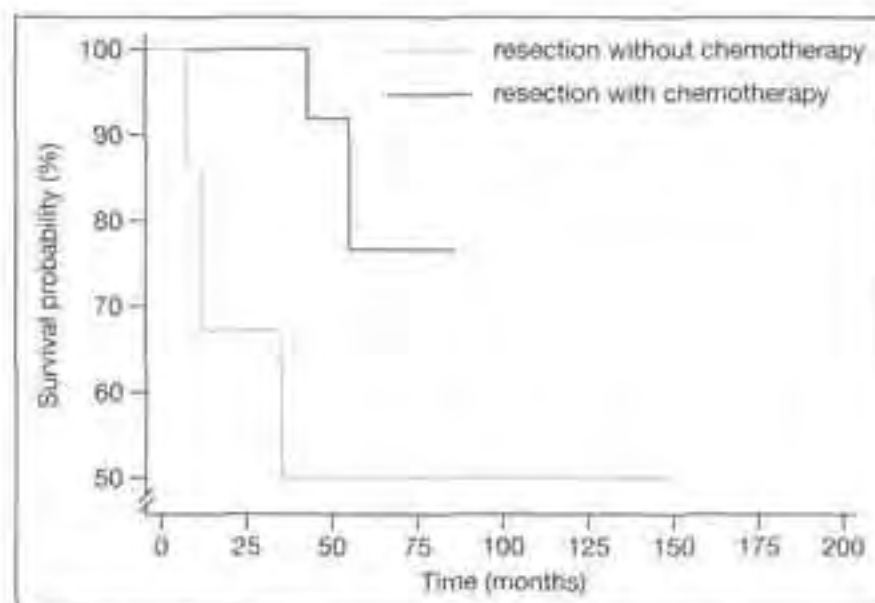
8–152) months. Survival rates were derived using the Kaplan-Meier survivorship analysis.

## RESULTS

Five patients attained excellent, 13 good to fair, and 2 poor functional outcomes. All those with proximal femoral tumours had satisfactory outcomes; the 2 patients with poor outcomes and half of those with fair outcomes had distal femoral tumours. Three of the 5 patients with proximal tibial tumours had excellent outcomes (Fig. 1). Regarding the 3 patients with proximal humeral tumours, one each had excellent, good, and fair outcomes. Overall, functional outcomes in distal femoral tumours were worse than at other sites (Table).

12 patients remained disease free and 3 had no evidence of disease after amputation for local recurrence. Five patients died of the disease with widespread metastases. The 5-year survival rate in the 6 patients who did not receive chemotherapy was 50%, and it was 76% in the remaining 14 patients who received chemotherapy (Fig. 2).

One patient with a distal femoral tumour developed wound infection that settled with antibiotics. One patient with a proximal tibial tumour developed skin necrosis, and was treated by skin cover. Three patients with distal femoral tumours and one with a proximal tibial tumour developed local recurrence; all 4 were treated by amputation. Two patients with total knee prosthesis had fractures of the femoral stem; one of whom underwent revision of the prosthesis (Table).



**Figure 2** The Kaplan-Meier 5-year survival rates of the malignant fibrous histiocytoma patients treated without chemotherapy and with chemotherapy were 50% and 76%, respectively.

## DISCUSSION

MFH is an unusual, high-grade primary tumour that arises either from fibroblasts or tissue histiocytes.<sup>6</sup> Histologically it consists of rounded, histiocyte-like, spindle-shaped, fibroblast-like cells, arranged in a storiform or whorled pattern.<sup>9</sup> MFH of bone was first described in 1972.<sup>10,11</sup> It usually arises from soft tissues and accounts for approximately 2% of all primary malignant bone tumours.<sup>1</sup> Up to 25% of these tumours occur secondary to pre-existent benign conditions (Paget's disease, irradiated bone, bone infarcts, enchondroma, and fibrous dysplasia).<sup>12–14</sup> Patients with such secondary tumours are often older

than those with the primary tumours<sup>15</sup>; the secondary type was noted in 3 of our patients, 2 of whom had a history of radiation and one had fibrous dysplasia.

The predilection of locations for MFH of bone is similar to that of osteosarcoma of bone. Commonly involved sites are: distal and proximal femur, proximal tibia, and proximal humerus; approximately 50% of the tumours occur around the knee.<sup>8,16</sup> In our series, the femur was the commonest site (60%), compared to 32 to 50% reported by others.<sup>8,17</sup> The mean age of presentation (42 years) and male predominance were similar to findings by others,<sup>8,15,17</sup> though female preponderance has also been reported.<sup>12</sup> A special feature of MFH of bone is the bimodal age pattern, which is unlike that for other malignant tumours of bone.<sup>17</sup>

MFH of bone has a tendency to infiltrate adjacent medullary regions gradually, without causing much tissue response or reactive ossification. Hence radiographs must be interpreted with care, as they may underestimate the true extent of disease involvement.<sup>12,18,19</sup> Also, being large destructive lesions, they may lead to pathological fractures (as in 5 of our patients).

The principles of treatment are similar to those for non-metastatic osteosarcoma.<sup>17</sup> Treatment decisions are based on the stage of the disease, as proposed by Enneking.<sup>5,6</sup> The mainstay of treatment is surgical resection or amputation. Chemotherapy appears to prolong survival,<sup>20</sup> and preoperative and adjuvant chemotherapy reduces the risks of microscopic residual and metastasis.<sup>17</sup> Favourable results are reported with limb salvage surgery and chemotherapy for stage-IA, -IB, or -II tumours.<sup>34</sup>

Endoprosthetic reconstruction following local resection of MFH of bone has been reported.<sup>21</sup> In our series, the prostheses were custom-made, using either stainless steel or titanium. Preoperative full-length radiographs were used to estimate the dimensions of the prostheses. Templates were used to manufacture the appropriate endoprostheses. CT and MRI helped estimate the extent of tissue involvement and hence facilitated planning of the level of resection. The accuracy of MRI in determining the extent of tumour spread and its effectiveness in preoperative planning has been reported.<sup>22,23</sup>

It is important to resect adequate surgical margins to prevent recurrence. Recurrence rates of 64% with inadequate margins, 19% with wide margins, and 6.5% with radical surgery have been described.<sup>9</sup> Also, when wide surgical margins were obtained, there was no difference in the recurrence rates between amputated and limb salvage patients. Two patients in our series with proximal humeral and distal femoral

MFH had marginal and contaminated margins respectively. Extensive resections to achieve wide surgical margins in these circumstances would have resulted in large bone defects, posing problems for reconstruction. These 2 patients refused amputation and wanted a functional limb, though they were aware of the increased risk of recurrence and death. One of them later developed recurrence and underwent amputation.

One technical problem with reconstruction for proximal tibial tumours is the restoration of the extensor mechanism.<sup>24</sup> Various methods have been proposed, including: special bands, tubes, and Dacron tapes augmented with bone grafts.<sup>24-26</sup> We used Dacron tapes to reattach the extensor mechanism to the prosthesis. Two of the 5 patients in our series with proximal tibial tumours had 20° and 10° of extensor lag, which resulted in fair and good functional outcomes, respectively.

Primary MFH of bone is often highly responsive to chemotherapy<sup>27</sup>; some even advocate chemotherapy as the primary treatment and surgery as adjuvant therapy.<sup>21</sup> In our series, patients treated before 1996 did not receive preoperative chemotherapy and had a less favourable 5-year survival rate of 50%; 3 died of the disease after 36, 12, and 8 months of follow-up and 2 developed local recurrence managed by limb ablation. When limb salvage surgery was combined with chemotherapy, the 5-year survival improved to 76%, comparable to other reports of 80% and 66% after 2 and 3 years, respectively.<sup>17</sup> Another series using surgery alone reported a 5-year survival of 28%, which improved to 57% when surgically treated patients also received chemotherapy.<sup>8</sup> Both series noted a worse prognosis in older patients with secondary tumours.

Prosthetic fracture is uncommon and reported in 1.6 to 16% of patients.<sup>26,28,29</sup> Poor component design, material properties, and high stresses due to bone deficiency after resection have been implicated as potential causes.<sup>30</sup> Some have reported reduction in implant failures with the use of larger core stems (>12 mm in diameter).<sup>26,31</sup> Further improvements in the material properties of the prostheses by using forged as opposed to cast material might decrease such complications.<sup>32</sup> Two patients in our series had prosthetic fractures; both were total knee prostheses. One was revised but later developed local recurrence treated by amputation. With the use of larger core diameter stems made of forged material, liability to this complication appears to have decreased.

Limb salvage with custom-made prosthesis was more emotionally acceptable than amputation. In

13 (65%) of our patients, it provided good stability, painless mobility, and an overall satisfactory functional outcome. Seven patients had poor outcomes due either to oncological or mechanical complications.

Patients who underwent limb salvage surgery with chemotherapy had higher survival rates than those treated with resection alone. This improved quality of life and provided a useful, functional limb.

## REFERENCES

- Schajowicz F. Tumours and tumour like lesions of bones and joints. New York: Springer; 1994:427-38.
- Bacci G, Picci P, Mercuri M, Bertoni F, Ferrari S. Neoadjuvant chemotherapy for high grade malignant fibrous histiocytoma of bone. *Clin Orthop Relat Res* 1998;346:178-89.
- Bramwell VH, Steward WP, Nooij M, Whelan J, Craft AW, Grimer RJ, et al. Neoadjuvant chemotherapy with doxorubicin and cisplatin in malignant fibrous histiocytoma of bone: a European Osteosarcoma Intergroup study. *J Clin Oncol* 1999;17:3260-9.
- Papagelopoulos PJ, Galanis EC, Sim FH, Unni KK. Clinicopathologic features, diagnosis, and treatment of malignant fibrous histiocytoma of bone. *Orthopedics* 2000;23:59-65.
- Enneking WF. A system of staging musculoskeletal neoplasms. *Clin Orthop Relat Res* 1986;204:9-24.
- Enneking WF, Spanier SS, Goodman MA. A system for the surgical staging of musculoskeletal sarcoma. *Clin Orthop Relat Res* 1980;153:106-20.
- Enneking WF. Modification of the system for functional evaluation of surgical management of musculoskeletal tumours. In: Bristol-Myers/Zimmer Orthopaedic Symposium. Limb salvage in musculoskeletal oncology. New York: Churchill Livingstone; 1987:626-39.
- Capanna R, Bertoni F, Bacchini P, Bacci G, Guerra A, Campanacci M. Malignant fibrous histiocytoma of bone. The experience at the Rizzoli Institute: report of 90 cases. *Cancer* 1984;54:177-87.
- Weiss SW, Enzinger FM. Malignant fibrous histiocytoma: an analysis of 200 cases. *Cancer* 1978;41:2250-66.
- Feldman F, Norman D. Intra- and extraosseous malignant histiocytoma (malignant fibrous xanthoma). *Radiology* 1972;104:497-508.
- Huvos AG. Primary malignant fibrous histiocytoma of bone: clinicopathologic study of 18 patients. *N Y State J Med* 1976;76:552-9.
- Spanier SS, Enneking WF, Enriquez P. Primary malignant fibrous histiocytoma of bone. *Cancer* 1975;36:2084-98.
- Boland PJ, Huvos AG. Malignant fibrous histiocytoma of bone. *Clin Orthop Relat Res* 1986;204:130-4.
- Huvos AG. Bone tumours: diagnosis, treatment, and prognosis. 2nd ed. Philadelphia: WB Saunders; 1991.
- Bridge JA, Herbert AS. Clinical oncology. 2nd ed. Churchill Livingstone; 2000:2224-8.
- Dahlin DC, Unni KK, Matsuno T. Malignant (fibrous) histiocytoma of bone—fact or fancy? *Cancer* 1977;39:1508-16.
- Huvos AG, Heilweil M, Bretsky SS. The pathology of malignant fibrous histiocytoma of bone. A study of 130 patients. *Am J Surg Pathol* 1985;9:853-71.
- Taconis WK, Mulder JD. Fibrosarcoma and malignant fibrous histiocytoma of long bones: radiographic features and grading. *Skeletal Radiol* 1984;11:237-45.
- Turculet V. Roentgenologic aspects of malignant fibrous histiocytomas of soft tissues and of bone [in French]. *J Radiol* 1981;62:429-36.
- Weiner M, Sedlis M, Johnston AD, Dick HM, Wolff JA. Adjuvant chemotherapy of malignant fibrous histiocytoma of bone. *Cancer* 1983;51:25-9.
- den Heeten GJ, Schraffordt Koops H, Kamps WA, Oosterhuis JW, Sleijfer DT, Oldhoff J. Treatment of malignant fibrous histiocytoma of bone. A plea for primary chemotherapy. *Cancer* 1985;56:37-40.
- van Trommel MF, Kroon HM, Bloem JL, Hogendoorn PC, Taminiau AH. MR imaging based strategies in limb salvage surgery for osteosarcoma of the distal femur. *Skeletal Radiol* 1997;26:636-41.
- Quan GM, Slavin JL, Schlicht SM, Smith PJ, Powell GJ, Choong PF. Osteosarcoma near joints: assessment and implications. *J Surg Oncol* 2005;91:159-66.
- Grimer RJ, Carter SR, Tillman RM, Sneath RS, Walker PS, Unwin PS, et al. Endoprosthetic replacement of the proximal tibia. *J Bone Joint Surg Br* 1999;81:488-94.
- Bickels J, Wittig JC, Kollender Y, Neff RS, Kellar-Graney K, Meller I, et al. Reconstruction of the extensor mechanism after proximal tibia endoprosthetic replacement. *J Arthroplasty* 2001;16:856-62.
- Plotz W, Rechl H, Burgkart R, Messmer C, Schelker R, Hipp E, et al. Limb salvage with tumour endoprostheses for malignant tumors of the knee. *Clin Orthop Relat Res* 2002;405:207-15.
- Urban C, Rosen G, Huvos AG, Caparros B, Cacavlo A, Nirenberg A. Chemotherapy of malignant fibrous histiocytoma of bone. A report of five cases. *Cancer* 1983;51:795-802.
- Roberts P, Chan D, Grimer RJ, Sneath RS, Scales JT. Prosthetic replacement of the distal femur for primary bone tumours. *J Bone Joint Surg Br* 1991;73:762-9.
- Gosheger G, Gebert C, Ahrens H, Streitbuenger A, Winkelmann W, Harges J. Endoprosthetic reconstruction in 250 patients with sarcoma. *Clin Orthop Relat Res* 2006;450:164-71.
- Athwal GS, Morrey BF. Revision total elbow arthroplasty for prosthetic fractures. *J Bone Joint Surg Am* 2006;88:2017-26.
- Capanna R, Morris HG, Campanacci D, Del Ben M, Campanacci M. Modular uncemented prosthetic reconstruction after resection of tumours of the distal femur. *J Bone Joint Surg Br* 1994;76:178-86.
- Sharma S, Turcotte RE, Isler MH, Wong C. Cemented rotating hinge endoprosthesis for limb salvage of distal femur tumors. *Clin Orthop Relat Res* 2006;450:28-32.